

**CAUSELESS HAPPINESS ORGANISATION-REGISTRATION FORM**

**SPONSERSHIP FORM FOR FINANCIAL ASSISTANCE FOR MEDICAL TREATMENT**

**PATIENT REG NO : CHO/585/**

**DATE : 18-11-2022**

**BENEFICIARY DEMOGRAPHY**

PATIENT'S NAME : ROHIT NISHAD

AGE: 4 YEARS

RELIGION : HINDU

GENDER : MALE ☒ FEMALE ☐ TRANSGENDER ☐



**PATIENT'S FAMILY DETAIL ( IN MIN 30 WORDS)**

Four members in family. Rohit is suffering with Eye cancer (Retinoblastoma) and his treatment is going on AIIMS Hospital. Rohit's father is currently unemployed and hardly earns bread for the family. They are in very miserable situation currently, kindly help child for his chemotherapy and eye surgery treatment.

**GUARDIAN 'S DETAIL :**

FATHER'S NAME: Mr. Suraj Kumar Nishad

AGE : 27yrs.

OCCUPATION: Unemployed

MOTHER'S NAME : Mrs. Reena

AGE : 31yrs.

OCCUPATION : Housewife

SIBLING : BROTHER ☐ SISTER ☐ 2 TRANSGENDER ☐

FAMILY INCOME: NIL

**TREATMENT DETAILS:**

PATIENT SUFFERING FROM :Eye Cancer (Retinoblastoma)

TREATMENT PRESCRIBED :Chemotherapy and Eye Surgery

APPROXIMATE EXPENSE FOR WHICH FINANCIAL ASSISTANCE REQUIRED: Rs.50000/-

TREATMENT IS DONE AT :AIIMS Hospital, New Delhi

**DECLARATION:**

I HEREBY DECLARE THAT THE INFORMATION GIVEN ABOVE IS TRUE AND TO THE BEST OF MY KNOWLEDGE.I AM NOT IN THE FINANCIAL POSTION TO ARRANGE FUNDS REQUIRED FOR THE TREATMENT OF MY CHILD.I AM FULLY AWARE OF THE FACT THE ORGANISATION WILL BE RAISING FUND FOR THE TREATMENT OF MY CHILD AND I HAVE NO OBJECTION WITH IT.

**(SIGN OF THE FATHER/GUARDIAN)**



सेवा में श्री मान दूखी महोदय

कॉन्सल्टिंग एप्रीनेशन अग्रीनार्ड जेशन

महोदय, सविनय नम्र निवेदन है। मेरा नाम सूरज कुमार निवाध  
और मेरे बेटे का नाम रोहित निवाध है।

जिनका उम्र 4 वर्ष है। मेरे बेटे का इलाज ALIMS  
हॉस्पिटल में चल रहा है वैसे को और का केन्द्र है।

मेरे एक असहायक गाबिर व्यक्ति है और मेरे बेटे का  
इलाज कराने में असमर्थ है।

और बहुत बड़ी परेशानी का सामना कर रहा है।

और मैं 2.5 लाख पैसे लेकर पैंचास हजार का

टीकर बच्चे का इलाज करवाया है और बच्चे के  
इलाज में लगा दिया है। और इलाज का खर्च 500000 तक  
डॉक्टर बताया है। और आप लोगों से निवेदन है  
कि सर हमारे कथन करें और आप सभी लोगों को

महना कृपा होगी पाणि

नाम - सूरज कुमार निवाध

पता - अवधपुर पो सरधारवाट जिला

गौरवपुर (व)

# ESTIMATE CERTIFICATE TO WHOM IT MAY CONCERN

This is to certify that Shri/Ms. Rohit Nishad Age 4yr Gender M

S/o, D/o, W/o..... is getting treatment under Ophthalmology Dept.

vide registration no. .... UHID No. 105817243

is suffering from (B) Grp DRB (C) enucleated

He/she has been advised for surgical items for IAC procedure of (1) cycles for IAC (Triple) regimen and the

approximate cost of the total treatment is Rs. 76430

(in words) Rupees..... Seventy six thousand four hundred thirty

# Item-wise break-up of expenditure of the estimate (if applicable) is as below.

✓ 1. INJECTION OMNIPAQUE/LOMERON 300mg- 50ml	1000RS
✓ 2. THREE WAY CONNECTOR(BD) -1	200RS
✓ 3. ECG ELECTRODES 6 PIECES	120RS
✓ 4. SHORT CONNECTING TUBES WITH 3 WAY-2	100RS
✓ 5. LONG CONNECTING TUBES WITH 3 WAY-2	160RS
✓ 6. LUER LOCK SYRINGES 10ml/0.1ml-1	100RS
✓ 7. MEDICUT 18G/PUNCTURE NEEDLE 18G-1	50RS
✓ 8. EXCHANGE GUIDEWIRE(TERMO) 150cm, 32 ANGLED-1	1500RS
✓ 9. DOUBLE LARGE BORE Y-CONNECTOR(MERIT)-1	100RS
✓ 10. FEMORAL SHEATH(ARROW) 5F X 7.5cm-1	1000RS
✓ 11. ENVOY 5F-1 (Codman)	11,300RS
✓ 12. MARATHON-1	28,000RS
✓ 13. HYBRID-1	25,300RS
✓ 14. INJECTION MELPHALON 50mg/10ml	2,500RS
✓ 15. INJECTION TOPOTECAN 2.5mg/2.5ml	4,000RS
✓ 16. INJECTION CARBOPLATIN 150mg/15ml	1,000RS
✓ 17. Mirage ev3.	
✓ 18. <del>envoy 5F (Codman)</del>	

76430

Note:

# This Estimate certificate is being issued to avail financial assistance for treatment only.

# The said estimate certificate is valid and applicable to avail financial assistance from Rashtriya Arogya Nidhi (RAN), Delhi Arogya Nidhi (DAN), State Illness assistance fund, Prime Minister's Relief Fund, Health Minister's Discretionary Fund (HMDF), MP local area development fund, CM relief fund, and fund from other sources.

# This Estimate Certificate is also applicable for Govt./PSU's employees and beneficiaries of ESI

# The Cheque is to be issued in favor of "Director AIIMS, New Delhi".





अखिल भारतीय आयुर्विज्ञान संस्थान, नई दिल्ली-110029

(REVISIT)

PASS ISSUE  
EMERGENCY, AIIMS

ALL INDIA INSTITUTE OF MEDICAL SCIENCES, NEW DELHI -110029

आपातकालीन विभाग



(DEPT. OF EMERGENCY MEDICINE)

UHID No:105817243

आपातकालीन नं. (Emergency No): 2022/030/0093839

दिनांक DATE: 17/11/2022

समय TIME: 11:12:21 AM

NON-MLC

105817243

नाम NAME: MR. ROHIT NISHAD

आयु AGE: 4 years 10 months 18 days

लिंग /SEX: M

medic

S/O : SURAJ KUMAR NISHAD

पता ADDRESS: मकान संख्या H.NO: AWADHAPUR, GORAKHPUR

गली / मुहल्ला STREET/MOH:

शहर/प्रखंड CITY/BLOCK:

पिन PIN:

273202

राज्य STATE:

DELHI

दूरभाष सं. PHONE NO:

7068342967

मोबाइल MOBILE NO:

7068342967

स्थान Location:

Paediatrics Emergency

द्वारा BROUGHT BY: Relative : FATHER

Criticality: Red / Yellow / Green

Triage: Responsive/ Unresponsive HR /min BP mmHg RR /min spO2 %

Shifted to Paeds/ Main/ New Emergency

Δ: K/40 B/L Retinoblastoma (↓ Paeds sur)

now c/o: - Fever since last night (upto 102°F)

Presenting Complaints

11-15 hr

Last Chemo on 08.11.22

- VCR/Carboplatin/Etoposide

Primary Assessment (ABCDE) : Assessment Pentagon

Airway	Circulation	Disability
Open & stable : <u>Yes</u> /No If No.....	HR <u>90</u> /min CFT <u>43</u> secs.	GCS <u>15/15</u>
Breathing: RR <u>24</u> /min Efforts: <u>Normal</u> /Poor/increased Auscultation: Air entry: <u>Normal</u> /poor/Differential	BP..... mmHg Peripheral pulse: Poor/ <u>Good</u> Central pulse: Poor/ <u>Good</u>	Pupil size...../min Pupillary Reactions.....
Added sounds: <u>None</u> /Stridor/Wheeze/Crackles SpO2 on Room air <u>96</u> %	Skin temp: <u>Warm</u> /cool Others	Motor activity: <u>Normal &amp; Symmetrical</u> /Asymmetrical/ Posturing/Flaccidity/Seizure
		Blood Sugar.....mg/dl Exposure: Temp..... <u>Afebrile</u> Colour: <u>Normal</u> /pallor/cyanosis /mottled Any other skin lesions.....

to 40 hr

Diagnosis

Adv:

CBC

1. Review E reports (for antibiotic) →

10.3 3980 45,000  
ANC=1794

Δ: Non-Neutropenic Fever

AIIMS FREE GENERIC MEDICINE RECEIVED  
NAME: 12/11/22 (11/11/22)  
DATE:

Dr. Rohan Grotra

Senior Resident

Department of Pediatrics

All India Institute of Medical Sciences, New Delhi-29

2. Cyp. Amoxycylav (5ml=200mg) 6ml PO QID x 5d

Cyp. PCM-DS (5ml=250mg) 5ml PO BID for fever



# AIIMS - DEPTT OF EMERGENCY MEDICINE

First Name: **ROHIT**  
 Gender: **Male**  
 Department:  
 Mode:

Last Name:  
 Age: 4Year(s)

Patient ID: 105817243  
 Date of Analysis: 17-11-2022 12:08

Para.	Result		Unit
1 <b>WBC</b>	3.98	L	10 <sup>9</sup> /L
2 Neu#	1.86	RL	10 <sup>9</sup> /L
3 Lym#	1.90	R	10 <sup>9</sup> /L
4 Mon#	0.21	R	10 <sup>9</sup> /L
5 Eos#	0.01	L	10 <sup>9</sup> /L
6 Bas#	0.00		10 <sup>9</sup> /L
7 IMG#	0.02	R	10 <sup>9</sup> /L
8 Neu%	46.9	RL	%
9 Lym%	47.7	R	%
10 Mon%	5.2	R	%
11 Eos%	0.2	L	%
12 Bas%	0.0		%
13 IMG%	0.4	R	%
14 <b>RBC</b>	3.48	L	10 <sup>12</sup> /L
15 <b>HGB</b>	10.3	L	g/dL
16 <b>HCT</b>	31.4	L	%
17 MCV	90.2		fL
18 MCH	29.5		pg
19 MCHC	32.8		g/dL
20 RDW-CV	0.166	H	
21 <b>RDW-SD</b>	56.6	H	fL
22 <b>PLT</b>	45	L	10 <sup>9</sup> /L
23 MPV	9.8		fL
24 PDW	16.0		
25 PCT	0.044	L	%
26 P-LCC	11	L	10 <sup>9</sup> /L
27 P-LCR	25.6		%
28 NRBC#	0.000		10 <sup>9</sup> /L
29 NRBC%	0.00		%

ब. रो. वि. कार्ड

O.P.D. Card

डा० राजेन्द्र प्रसाद नेत्र विज्ञान केन्द्र  
अ० भा० आयु० सं०, नई दिल्ली - 110029

Dr. Rajendra Prasad Centre for Ophthalmic Sciences  
A.I.I.M.S., New Delhi-110029



अनुभाग व दिन  
Section and Day  
बुधवार व शनिवार VI  
Wednesday & Saturday

कमरा नंबर  
Cabin No.

यू०एच०आई०डी० संख्या

UHID No. 105817 243

आचार्य राधिका टंडन का एकक

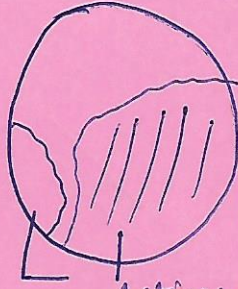
Prof. Radhika Tandon's Unit

रोगी का नाम Name of the Patient Rohit	पुत्र/पुत्री/पत्नी S/D/W	लिंग Sex M	आयु Age 44	पता Address
दिनांक DATE 28/7/22	निदान DIAGNOSIS (R) Partially Regressing (L) Enucleated			

उपचार Treatment


EUA done & unit-6 by Dr. Loui.  
No of chemotherapy. (1)  
Last chemo date 6/7/22

IAC ⊖  
EBRT ⊖  
Periocular/ intra vitreal ⊖  
Last EUA = 25/3/22



Mass just to lens.

Active lesions



enucleation in Nepal in 2017

कृपया इस कार्ड को सुरक्षित रखें तथा अस्पताल में दिखाने के समय हर वक्त साथ लायें।

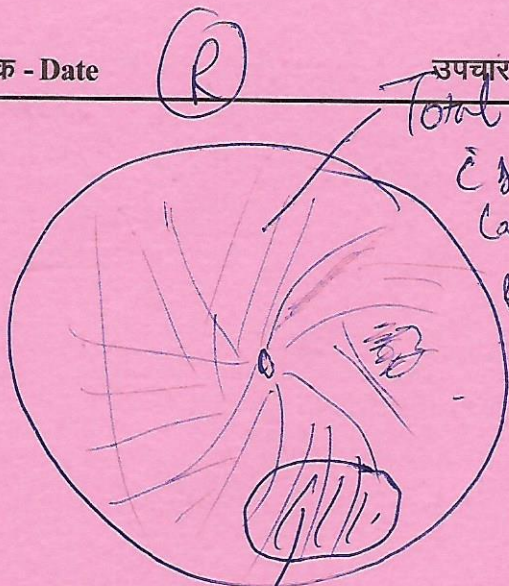
Kindly keep this Card safely and bring it on your follow-up visits.

- धूम्रपान निषेध 1. No Smoking
- कूड़ा कर्कट केवल कूड़ेदान में ही डालें 2. Use Dustbin
- थूकिये नहीं 3. No Spitting



दिनांक - Date

उपचार - Treatment



Total RD  
E subretinal  
Calcification:-  
f. neds.



Enucleated

~~Regrowing~~ max

Vitrious cluding (P)  
regrowing pattern

Adv

Old RAK Room (7/10/14) Wed/Sat

Continue with (2) more cycles of  
systemic chemotherapy

↓

~~Left demo 24/10/2020~~

Rw in (143) RD clinic wed/monday.  
2pm. for DPA LVA

Dr LVA

16/sep/2020

1400-1200  
1400-1100

Neha

नेत्र ईश्वरीय सर्वश्रेष्ठ उपहार है जिनका मनुष्य जीवन में दान करना परमश्रेष्ठ है।

इनकी पूर्ण रक्षा कीजिए ताकि ये आपकी रक्षा कर सकें।

Eyes are God's most precious gift to man kind and eye donation is the most noble deed.

Take full care of them so that they can take care of you.



ब० रो० वि० कार्ड

O.P.D. Card

डा० राजेन्द्र प्रसाद नेत्र विज्ञान केन्द्र  
अ० भा० आयु० सं०, नई दिल्ली - 110029

Dr. Rajendra Prasad Centre for Ophthalmic Sciences  
A.I.I.M.S., New Delhi-110029

यू०एच०आई०डी० संख्या

UHID No. 105 817 243

दृष्टि



नेत्र असुख उपहार है  
जो आप ही दे सकते हैं

अनुभाग व दिन

Section and Day

बुधवार व शनिवार

Wednesday & Saturday

कमरा नंबर

Cabin No.

आचार्य राधिका टंडन का एकक

Prof. Radhika Tandon's Unit


रोगी का नाम Name of the Patient	पुत्र/पुत्री/पत्नी S/D/W	लिंग Sex	आयु Age	पता Address
Rohit		M	44	
दिनांक DATE	निदान DIAGNOSIS	(RE) Group D: (Partially regressing) RB (LE) Enucleated		
16/9/22	उपचार Treatment EVA ↓ unit-6 No of chemo: 6 last chemo: 25/8/22 IAC ⊕ EBRT ⊕ Periocular/ Intravitreal inj. ⊕ last EVA: 28/7/22 OD OS Total RD ⊕ sub retinal calcification of seeds			

कृपया इस कार्ड को सुरक्षित रखें तथा अस्पताल में दिखाने के समय हर वक्त साथ लायें।

Kindly keep this Card safely and bring it on your follow-up visits.

- धूम्रपान निषेध
- कूड़ा कर्कट केवल कूड़ेदान में ही डालें
- थूकिये नहीं
1. No Smoking
2. Use Dustbin
3. No Spitting



REOPD/w Dr LoniLE

Enucleated

Partially Regressing lesion

# old RAO  
OPD

continue one cycle of systemic chemo  
R No 7/10/14 (Wed/Sat)



R/v in (143) RB Clinic wed/Mon for DFEVA

Adv

g Mycin TDS x 5 days (RE)  
obb

16/9/22

नेत्र ईश्वरीय सर्वश्रेष्ठ उपहार है जिनका मनुष्य जीवन में दान करना परमश्रेष्ठ है।

इनकी पूर्ण रक्षा कीजिए ताकि ये आपकी रक्षा कर सकें।

Eyes are God's most precious gift to man kind and eye donation is the most noble deed.

Take full care of them so that they can take care of you.



ब० रो० वि० कार्ड

O.P.D. Card

डा० राजेन्द्र प्रसाद नेत्र विज्ञान केन्द्र,

अ० भा० आयु० सं०, नई दिल्ली - ११००२९

Dr. Rajendra Prasad Centre for Ophthalmic Sciences

A.I.I.M.S., New Delhi-110029

दृष्टि



नेत्र अमृत्य उपहार है  
जो आप ही दे सकते हैं

अनुभाग व दिन  
Section and Day  
बुधवार व शनिवार  
Wednesday & Saturday

VI

कमरा नंबर  
Cabin No.

यु एच आई डी संख्या

UHID No.

105817243

आचार्य राधिका टंडन का एकक

Prof. Radhika Tandon's Unit

रोगी का नाम Name of the patient	पुत्र/पुत्री/पत्नी S/D/W	लिंग Sex	आयु Age	पता Address
Rohit		M	44/04	
दिनांक DATE	निदान DIAGNOSIS	उपचार Treatment		
4/11/22	(R) gp D (Tarsal regression) RB (L) Enucleated			
	<p>EVA limit 6 by No. 9 chemo → 7 last chemo → 24/9/22 IAC ⊖ EBRT ⊖ Intraorbital / Periorbital inj ⊖ last EVA - 16/9/22</p> <p>Total RD subretinal calcified seeds Partially regressing lesion</p> <p>Enucleated in Nepal in 2017</p>			

कृपया इस कार्ड को सुरक्षित रखें तथा अस्पताल में दिखाने के समय हर वक्त साथ लायें।

Kindly keep this Card safely and bring it on your follow-up visits.

१. धूम्रपान निषेध २. कूड़ा कर्कट केवल कूड़ेदान में ही डालें ३. थूकिये नहीं



दिनांक - Date

C/Dw D Com


उपचार- Treatment

Total RD &  
subretinal

RE

LE

Calcified  
seeds



Unnucleated

Partially Regressing lesion

Adv

continue one cycle of systemic chemo  
R No 7/10/14 (Wed/Sat)

Q<sup>25</sup>

Andiff

Does not R/v in month after after NRC R/v.  
Monday. 10am Ward 1A

Q VER.

Date taken

for 17/10/15

Rx  
again TBC x (BE)

CE MRI (Brain + Orbit)

Int suppressed & dms into  
through optic chiasm gland +  
axial sagittal  
+ coronal planes

4/11/22

नेत्र ईश्वरीय सर्वश्रेष्ठ उपहार है जिनका मनुष्य जीवन में दान करना परमश्रेष्ठ है।

इनकी पुर्ण रक्षा कीजिए ताकि ये आपकी रक्षा कर सकें।

Eyes are God's most precious gift to man kind. Take full care of them

So that they can take care of you





अखिल भारतीय आर्य वैज्ञान संस्थान, नई दिल्ली-110029

(REVISIT)

ALL INDIA INSTITUTE OF MEDICAL SCIENCES, NEW DELHI -110029

आपातकालीन विभाग

(DEPT. OF EMERGENCY MEDICINE)

आपातकालीन (Emergency No): 2022/030/0091236

दिनांक DATE: 09/11/2022



UHID No:10581724

समय TIME: 11:20:31 AM

NON-MLC

नाम NAME: MR. ROHIT NISHAD

S/O : SURAJ KUMAR NISHAD

पता ADDRESS: मकान संख्या H.NO: AWADHAPUR, ORAKHPUR

शहर/प्रखंड CITY/BLOCK:

राज्य STATE:

मोबाइल MOBILE NO:

DELHI

7068342967

गली / मुहल्ला STREET/MOH:

पिन PIN:

273202

दूरभाष सं. PHONE NO:

7068342967

स्थान Location:

Paediatrics Emergency

द्वारा BROUGHT BY: Relative : FATHER

Criticality: Red / Yellow / Green

Triage: Responsive/  
Unresponsive

HR

/min

BP

mmHg RR

/min

spO2

%

Shifted to Paeds/ Main/ New Emergency

Presenting Complaints

Vomiting since 8pm last night  
10-12 episodes

On 3<sup>rd</sup> episode

No h/o diarrhea

Revised Etoposide  
yesterday

No h/o fever

No h/o blood in vomitus

No signs of  
dehydration

No h/o loss of consciousness

Primary Assessment (ABCDE) : Assessment Pentagon

<p><b>Airway</b></p> <p>Open &amp; stable : <u>Yes</u>/No If No.....</p> <p><b>Breathing:</b> RR <u>18</u>/min <b>Efforts:</b> <u>Normal</u>/Poor/increased <b>Auscultation:</b> Air entry: <u>Normal</u>/poor/Differential</p> <p>Added sounds: <u>None</u>/Stridor/Wheeze/Crackles</p> <p>SpO2 on Room air <u>98</u>%</p> <p>18/11/22</p>	<p><b>Circulation</b></p> <p>HR <u>130</u> /min</p> <p>CFT.....secs.</p> <p>BP <u>105/66</u> mmHg</p> <p>Peripheral pulse: Poor/<u>Good</u></p> <p>Central pulse: Poor/Good</p> <p>Skin temperature: <u>Warm</u>/cool</p> <p>Others</p>	<p><b>Disability</b></p> <p>GCS.....</p> <p>Pupil size...../min</p> <p>Pupillary Reactions.....</p> <p><b>Motor activity:</b> Normal &amp; Symmetrical/Asymmetrical/ Posturing/Flaccidity/Seizure</p> <p>Blood Sugar.....mg/dl</p> <p><b>Exposure:</b> Temp..... Colour: Normal/pallor/cyanosis /mottled Any other skin lesions.....</p>
---	---	--

Diagnosis

Δ - CIN V

IV cannula  
CBC

- IV Emeset 4mg stat  
- IV Pantop 20mg stat

Reassess oral intake

→ Good Emeset 4mg po stat  
Pantop 20mg po stat

SR



9/11/22  
Red Emergency

F/U Rb  
received CEV on 7/11/22 & 8/11/22.

Weight: 15kg.

• vomiting 5 episodes since morning  
Oral acceptance limited due to vomiting  
Urine output ⊕

o/e: alert  
dull, E4V5M6  
oral mucosa moist  
no signs of dehydration  
PR: 100/1, PV: good, RR: 20/1, CFT 2s;  
peripheries warm

Imp: CINV

Adv

CBC  
11.4 6900 272000  
4680

VBG: not done

5:40 PM  
AG  
✓ 1) Inj. PANTOPRAZOLE 15mg IV stat  
✓ 2) Inj. ONDANSETRON 4mg IV stat  
✓ 3) Inj. DEXAMETHASONE 3mg IV stat  
✓ 3) IVF DNS + 1:100 KCL at 55 ml/hr

4) I/O charting

5) Assess oral acceptance  
ORS 75ml/vomitus

J. ONDANSETRON 4mg 1 — 1 — 1  
J. DEXAMETHASONE 4mg 1 — 0 — 1  
J. PANTOPRAZOLE 20mg 1 tab OD  
(on an empty stomach) } x 5d

6) If oral acceptance fair, symptoms subside  
can be sent home.  
Reassess vitals before sending home.

7) To get G-CSF from Co/daycare from  
today

CINV  
R: I. olanzapine (5 mg) 1/3 stat  
per se

Dr. K. Padma Sagarika  
Senior Resident, DM Pediatric Oncology  
Dept. of Pediatrics, AIIMS - DMC 96978

10 PM.



अखिल भारतीय आयुर्विज्ञान संस्थान, नई दिल्ली-110029  
ALL INDIA INSTITUTE OF MEDICAL SCIENCES, NEW DELHI-110029

नाम Rohit  
Name

उम्र  
Age

सर्विस  
Service

दिनांक  
Date

यू.एच.आई.डी. नं.  
UHID No.

प्रोफेसर इंचार्ज  
Professor I/C

Notes written by .....

CLINICAL NOTES

9/11/22  
10 PM

Case reviewed by SR, Pcd on

C/O - Metastatic R.B.  
post C# 8 - HD CE

P/C - vomit<sup>7</sup> x 1 d  
headache : even today

O/E - PR - 126  
RR - 24/min  
variable  
No NR  
Tone - (M) (M)  
DTR - (+) (+)

? Refractory CINV

?? disease progression

Adv: - T. olanzepine (5) 1/3<sup>rd</sup>  
tab stat

↓  
if no improvement  
plan: CECT head.

SK  
(Dr Shukla)





सरीरमाद्यं खलु धर्मसाधनम्

एकक/Unit

विभाग/Dept.

नाम/Name

# अ० भा० आ० सं० अस्पताल/A.I.I.M.S. HOSPITAL बहिरंग रोगी विभाग /Out Patient Department

अस्पताल के अन्दर धूम्रपान मना है।/SMOKING IS PROHIBITED IN HOSPITAL PREMISES



एक कदम स्वच्छता की ओर

रोगी विवरण/Details



UHID: 105817243

Dept No: 20220030012320

कमरा / Room

OPR-6

14  
Unit-III  
Paediatric  
Queue No: F22  
30/07/2022

LH2008220612

105817243



LC2008220950

105817243



ROHITNISHAD

ROHIT NISHAD

4Y 7MD / M (पुरुष)

S/O SURESH KUMAR NISHAD

Add: AWADHAPUR, GORAKHPUR, DELHI,

Pin 273202, INDIA

Mob: 7068342967

Follow Up...

General

R 0

Reporting: 9 00

AM-10 00 AM

निदान/Diagnosis

दिनांक/Date

उपचार/Treatment

13.8.22

debarb u side not  
run

26  
On sept 2022  
Ht - 100cm

रोगी विवरण/Details



UHID: 105817243

Dept No: 20220030012320

कमरा / Room

14  
Unit-III  
Paediatric  
Queue No: F44  
17/08/2022

ROHIT NISHAD

4Y / M (पुरुष)

S/O SURESH KUMAR NISHAD

Add: AWADHAPUR, GORAKHPUR, DELHI,

Pin 273202, INDIA

Mob: 7068342967

Follow Up...

General

0

Reporting: 8 00

AM-9 00 AM

clo

Bilateral RB

Details in POE copy

CBC on 20th

14.8

CBC  
LFT

27



Pradhan Mantri Jan Arogya Yojana  
Ayushman Bharat  
PM-JAY  
प्रधानमंत्री जन आरोग्य योजना  
(pmjay.gov.in)

CLEAN AND GREEN AIIMS / एम्स का यही संकल्प, स्वच्छता से काया कल्प

अंगदान-जीवन का बहुमूल्य उपहार/ORGAN DONATION - A GIFT OF LIFE

O.R.B.O., AIIMS, 26588360, 26593444, www.orbo.org Helpline - 1060 (24 hrs service)



My Hospital  
meraaspatal.nhp.gov.in



बाल चिकित्सा विभाग



UHID: 105817243  
Dept No: 20220030012320

कमरा / Room

14  
Unit-III  
Paediatric  
Queue No: F53  
03/09/2022

ROHIT NISHAD

4Y 8M4D / M(बुद्ध)

S/O SRI RAKHI MAR NISHAD

Add: AWADHAPUR, GORAKHPUR, DELHI  
Pin 273202, INDIA

बुध, शनि

Wed Sat (बुध, शनि)



Mob: 7068342967 Follow Up... General F0 Reporting: 8:00 AM-9:00 AM

Recd- 105/22

14.11

48

बाल चिकित्सा विभाग



UHID: 105817243  
Dept No: 20220030012320

कमरा / Room

14  
Unit-III  
Paediatric  
Queue No: F17  
17/09/2022

ROHIT NISHAD

4Y 8M 18D / M(बुद्ध)

S/O SRI RAKHI MAR NISHAD

Add: AWADHAPUR, GORAKHPUR, DELHI  
Pin 273202, INDIA

बुध, शनि

Wed Sat (बुध, शनि)



Mob: 7068342967 Follow Up... General F0 Reporting: 8:00 AM-9:00 AM

28

14.6.19





# GOYAL MRI & DIAGNOSTIC CENTRE

B-1/12, SAFDARJUNG ENCLAVE, NEW DELHI - 110029

Phone : 40771234, 26107559 E-mail : goyalmri@yahoo.com

**Dr. Ankur Gadodia**  
MD (AIIMS), DNB, FRCR

**Dr. Pranay R Kapur**  
MBBS, DNB

15.11.2022

**MR. ROHIT, 4 YRS 10 MONTHS / M**

**UID: 11.22.0552**

## **M.R. OF THE CRANIUM WITH CONTRAST**

Axial T1, FLAIR & FSE T2 weighted scans of the brain were studied and these were correlated with coronal and sagittal FSE T2 weighted scans. Additional T1 weighted axial, coronal & sagittal scans were obtained following administration of contrast (10mL Omniscan). No immediate adverse contrast reaction was noted.

### **Follow up case of bilateral retinoblastoma, status post op and post chemotherapy.**

Left globe is not visualize – status post-op. No definite recurrent / residual mass lesion is seen.

Right globe is normal in size. Right retinal detachment is seen with subretinal hemorrhage. No definite mass lesion is seen. Right optic nerve is unremarkable.

Cerebral and cerebellar parenchyma is unremarkable. No acute infarct is seen on diffusion weighted images.

Bilateral basal ganglia and thalami are normal in signal intensity.

The corpus callosum, sellar and suprasellar regions, and skull base are normal. No midline shift. No acute intracerebral hemorrhage.

Brainstem is unremarkable. Skull base arteries demonstrate normal flow void.

Visualized portions of the orbits are unremarkable.

Mucosal thickening is seen in bilateral maxillary and ethmoid sinuses.

### **IMPRESSION:**

- No definite recurrent / residual mass lesion in the left orbit.
- Right retinal detachment with subretinal hemorrhage. No definite mass lesion is seen.

**Recommended : Comparison with previous scans**

**Clinical correlation is necessary**

  
**DR. ANKUR GADODIA**  
MD (AIIMS), DNB, FRCR (UK)

This is a professional opinion and not the diagnosis. Findings should be clinically correlated.

Facilities Available : 3.0 Tesla GE Pioneer MRI, 32 Slice CT Scan, Bone Densitometry (DEXA), Ultrasound with Color Doppler, Digital X-Ray, Echocardiography, ECG, PFT, EEG, NCV, EMG, Pathology Lab (NABL & NABH Accredited)



Cycle 8

8/12/22 D, { Inj v CR — 0.4 mg  
 " carboplatin — 400 mg  
 " E lig mite — 180 mg

D2 8/11 Inj E lig mite 180 mg  
 cont rephat

127 brain

SA  
 Dr Monahan  
 (7)

Inj GLSA.

TS/gy SC OD WH ARE  
 moving

10/11	<u>8 10/11</u>
11/11	_____
12/11	_____
13/11	_____
14/11	_____



- 16/4/22
- 2/ Beladua eggs
  - nails not cut
  - hygiene explained
  - 100 Seprox-Ap
  - cycle completed on 28/9.
  - no fresh complaints.

post C# 8 HD-C  
advised G.C.S.A  
X50  
not taken

No fever

latest CBC-NAB

No complaints

- Adv: - MRI - RC desan  
- ophtal counsel  
- Father advised  
to consider E/  
if advised by  
ophtal team  
- N/V on 26/11/22

S/S Dicitin  
16/4/2022

Wt: - 15kg

Current Intake : 1250 kcal and 32g

Recommended Intake : 1300 kcal and 39g

Thyptin 2/day

Diet Nengoni

Counseling done.

JH  
16/4/22



# अ० भा० आ० सं० अस्पताल/A.I.I.M.S. HOSPITAL

## बहिरंग रोगी विभाग /Out Patient Department

अस्पताल के अन्दर धूम्रपान मना है।/SMOKING IS PROHIBITED IN HOSPITAL PREMISES



Room No-14 (Follow-up)

OPR-6

105/22

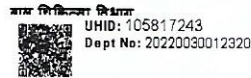
एकक/Unit III  
विभाग/Dept. Peds

ब० र० वि० पंजीकृत सं०/O.P.D. Regn. No. 105817243

नाम/Name	पिता/पुत्र/पत्नी/पुत्री F/S/W/D of	लिंग Sex	आयु Age	पता/Address
Rohit Nishad				

निदान/Diagnosis

दिनांक/Date	उपचार/Treatment
<p>30 NOV 2022</p> <p>18</p> <p>pt. can go home.</p> <p>2</p> <p>- Reritury Concession Issued on 30/11/2022. Retissued on 21/12/22</p>	<p>N/V - 14/11/22</p> <p>RP visit pending today</p> <p>ndh</p> <p>- N/V 17/11/22</p>



उपचार/Room  
UHID: 105817243  
Dept No: 20220030012320

ROHIT NISHAD  
4Y 11M 15D / M (पुरुष)  
S/O: SURAJ KUMAR NISHAD  
Add: AWADHAPUR, GORAKHPUR, DELHI  
Pin 273202, INDIA

Mob: 7068342967 Follow Up... General 14/11/22 Reporting: 8:00 AM-9:00 AM



Reporting: 8:00 AM-9:00 AM



आर्य समाज विद्यालय



UHID: 105817243  
Dept No: 20220030012320

कमरा / Room

14  
Unit-III  
Paediatric  
Queue No: F8  
17/12/2022

ROHIT NISHAD

4Y 11M 18D / M(बुद्धि)  
S/O SURAJ KUMAR NISHAD  
Add: AWADHAPUR, GORAKHPUR, DELHI,  
Pin 273202, INDIA

Mob: 7068342967 Follow Up... General 10

Reporting: 8 00  
AM-9 00 AM



Wad S. 17/12/2022

Refer patient note book.

Adv

- 1) CBC/RFT/LFT → (27)
- 2) F/U on 4/1/23 with reports.

K. Padma Sagarika  
SR/Red Bn

C/D/W Prof. R. Seth

- To meet Dr. Bhawna (Consultant, RSC)  
in Room 32 (case discussed)

K. Padma Sagarika  
SR/Red Bn

(5)



Dr. Rajendra Prasad Centre For Ophthalmic Sciences  
ALL INDIA INSTITUTE OF MEDICAL SCIENCES (AIIMS), New  
Delhi, 110029

Discharge Report  
PROVISIONAL DISCHARGE CERTIFICATE

UHID : 105817243  
Name: Mr. ROHIT NISHAD  
Age/Sex: 4 years 11 mons 14 days / Male  
Ward Name: 1A  
Address: AWADHAPUR, GORAKHPUR, DELHI,  
Pin: 273202, INDIA  
Mobile No: 7068342967  
Date of Admission: 10/12/2022 12:36:13 PM  
Date of Discharge : 13/12/2022 03:58:00 PM

Cr No: R-043807-22  
Department: R. P. Centre (Eye Centre)  
Unit: Unit-VI  
Bed No.: 123

Drug Allergy, if any :- []

R-P-C

105817243

ICD Code: C69.2  
ICD Description: Malignant neoplasm Retina

Diagnosis

✓ RE GROUP D RB  
LE ENUCLEATED

Investigation

Systemic : NIL SYSTEMIC ILLNESS

Ocular

VA -  
RE - DOES NOT FOLLOW LIGHT  
IOP -  
RE - DIG N

Treatment/Operative Procedure

Surgeon  
Date 13/12/2022

Surgery

EUA

24/12/22 (100)

Condition at Discharge

Vision: VA -  
RE DOES NOT FOLLOW LIGHT  
Anterior Seg. : SAME AS ON ADMISSION

IOP: RE  
DIG N  
Posterior Seg. : SAME AS ON ADMISSION

Advice During Discharge

Oral  
Follow Up : IN RB CLINIC WITH IAC DATE IN 142B AT  
1:30PM, MON /WED

Topical  
Position : RE  
E/D VICAMOX 4T/D X 1WK - 8-12-48

6<sup>th</sup> floor CMC - Prof Garg was  
in office for 2A date  
EUA -  
Counseling i PSC  
Retam - Media haze  
Requesting pattern  
CRD/W De Coni  
Plan for R IAC

Prepared By: Dr. Shweta Sandhu

Signature of Senior Resident

Dr. R. P. Centre for Ophthalmic Sciences  
Date & Time: 29

VER = 5.6 μ 97.7ms

OAC Set (1st wk of Feb, 23)  
mon/wednesday

DoA - 24-12-22

Ward 1A

8:00 am

13-12-2



A.I.I.M.S. - NEW DELHI  
DEPARTMENT OF LABORATORY MEDICINE  
CLINICAL CHEMISTRY  
EMERGENCY AND WARD

PATIENT:

PHYSICIAN:

ID:

ID:

ADDRESS:

ADDRESS:

BIRTH DATE:

COMMENTS:

AGE:

SEX:

ROOM:

SAMPLE ID: 514/10

PRIORITY: \*\*ROUTINE\*\*

COLLECTED ON:

FLUID: Serum

TEST START DATE/TIME: 10/12/2022 21:51:07

HEMOLYSIS (H): 25

ICTERUS (I): <2

TURBIDITY (T): <20

ASSAY		RESULT	H I T	RANGES
Urea		32.3 mg/dL		15.0-46.0
Creatinine	LO	0.3 mg/dL		0.6-1.2
Sodium		140 mmol/L		137-145
Potassium		4.3 mmol/L		3.5-5.1
Chloride	HI	108 mmol/L		98-107
Calcium		8.9 mg/dL		8.4-10.2
Total Bilirubin		<0.1 mg/dL		0.0-1.4
Uric Acid		3.8 mg/dL		3.5-8.5
Total Protein		7.1 g/dL		6.3-8.1
Albumin		4.6 g/dL		3.5-5.0
Phosphorus	HI	5.9 mg/dL		2.5-4.5
Unconj. Bilirubin		0.0 mg/dL		0.0-1.1
Conjugated Bilirubin		0.0 mg/dL		0.0-0.3
AST		53 U/L		17-59
ALT		34 U/L		0-50
Alkaline Phosphatase	HI	192 U/L		38-126
ALB/GLOB Ratio		1.8		0.8-2.0
Direct Bilirubin		NO RESULT		
Globulin	LO	2.5 g/dL		3.0-3.7

End of Report

PAGE 1

PRINT DATE/TIME: 10/12/2022 22:27:52

No.: ROHIT/0438007

ID:

Sample Comment:

Ward:

Rack: 42

Aims, Laboratory Medicine XN series

Position: 7 2022/12/10 18:29:01 W

Doctor:

Birth:

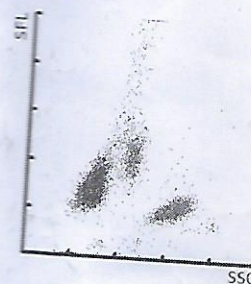
Sex:

Nickname: XN-2000-1-L

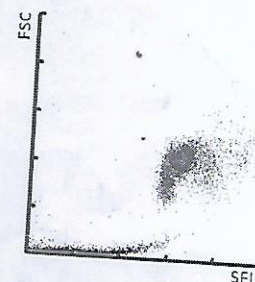
Positive  
Morph.

WBC	5.32	[10 <sup>3</sup> /uL]		
RBC	3.82	[10 <sup>6</sup> /uL]		
HGB	10.9	[g/dL]		
HCT	33.4	[%]		
MCV	87.4	[fL]		
MCH	28.5	[pg]		
MCHC	32.6	[g/dL]		
PLT	185	[10 <sup>3</sup> /uL]		
RDW-SD	53.0	[fL]		
RDW-CV	16.7	[%]		
PDW	11.4	[fL]		
MPV	10.2	[fL]		
P-LCR	27.6	[%]		
PCT	0.19	[%]		
NRBC	0.00	[10 <sup>3</sup> /uL]	0.0	[%]
NEUT	1.50 *	[10 <sup>3</sup> /uL]	28.1 *	[%]
LYMPH	3.08 *	[10 <sup>3</sup> /uL]	57.9 *	[%]
MONO	0.69 *	[10 <sup>3</sup> /uL]	13.0 *	[%]
EO	0.03	[10 <sup>3</sup> /uL]	0.6	[%]
BASO	0.02	[10 <sup>3</sup> /uL]	0.4	[%]
IG	0.02 *	[10 <sup>3</sup> /uL]	0.4 *	[%]


WDF




WNR



RBC



PLT



WBC IP Message  
Blasts/Abn Lympho?  
Atypical Lympho?

RBC IP Message

PLT IP Message



13/12/22

② VER  $\cdot$  5.6m 97.7ms

EVA - Journal scanning  $\bar{c}$  PSC

Ritman - media haze.

Regressing pattern

1

C/D/W in Loni

Dif ② IAC.

- No fresh complaints.
- CBC Report pending

26/12/22

④ group E enucleated ..

② gp D.

Post 8 cycles CEV (last 7/11/22) .

Last EVA (4/11/22)

Partially regressing lesion ✓

Calcified seeds, total RD.

MRI done - called on Monday for RPC review.

RC :

No leptomeningeal / parenchymal involvement

Rt side retinal hemorrhage ⊕

No intra-ocular mass, no ONI.

Left cut-end ON focal involvement.

②

Review 28/11/22 2pm [after RPC review]

± CBC/RFT/LFT meval  
22



30/12/22  
 1) 200 Septan  
 2) 2% betadine gargle  
 3) photo copy

NRC - @ i/ocular  
 ring @ = RD  
 No ONI/extras  
 invov

Planned for ECA  
 VER + IAC at R

Adv: - cont. septan  
 - N/V on 14/11/22

14/12/22  
 Counseling done  
 → Betadine gargle 2%  
 → Sitz bath  
 On Septan A/D  
 No fresh complain

B/L IORB; (L) group E - enucleated  
 (R) group D - post 8# HDCEV

recent EVA 13/12/22

no vision in (R) eye.

planned for IAC.

recent MRI  
 15/11/22

↓  
 (R) IORB,  
 no optic N. involvement

17/12/22  
 Cycle completed  
 File is complete

K. Radhakrishna  
 Sr. Med Off

Adv

1) F/U in RPC for IAC.

2) F/U in Rd 3 OPD on  
 04/01/2023 with CBC/RFT/LFT  
 reports.

C/D/w Prof. R. Seth

• To consider enucleation of (R) eye as  
 there is vision loss in (R) eye, to avoid  
 the toxic effects of chemotherapy.

• To meet Dr. Bhawna (Consultant, RPC)  
 28 in Room 32 today.